

Expression of the Forssman antigen in gastrointestinal cancer

Tiago Silva¹, Diana Martins^{1,2,3,4}, Paulo Teixeira^{1,5}, Cristiana Mourato¹, Rúben Nunes¹, Carolina Melo¹, Clara Rocha^{6,7}, Simone Oliveira⁸, Inês Mónica⁹, Lucília Conceição⁸, Daniel Almeida¹⁰, Inês Oliveira¹⁰, Fernando Mendes^{1,2,3,4,11}

Politécnico de Coimbra, ESTeSC, DCBL, Rua 5 de Outubro - SM Bispo, Apartado 7006, 3046-854 Coimbra, Coimbra, Portugal¹. University of Coimbra, Coimbra Institute for Clinical and Biomedical Research (iCBR) area of Environment Genetics and Oncobiology (CIMAGO), Biophysics Institute of Faculty of Medicine, Coimbra, Portugal². University of Coimbra, Center for Innovative Biomedicine and Biotechnology (CIBB), Coimbra, Portugal³. Clinical Academic Center of Coimbra (CACC), Coimbra, Portugal⁴. Pathological Anatomy Service from Coimbra Hospital and University Center⁵. Polytechnic of Coimbra, ESTeSC, Department Complementary Sciences, ESTeSC, Rua 5 de Outubro, SM Bispo, Apartado 7006, 3046-854, Coimbra, Portugal⁶. Institute for Systems Engineering and Computers at Coimbra, Coimbra, Portugal⁷. Surgical Service, Hospital Distrital da Figueira da Foz, E.P.E., Figueira da Foz, Portugal⁸. Medical Service, Hospital Distrital da Figueira da Foz, E.P.E., Figueira da Foz, Portugal⁹. Anatomopathological Diagnosis Center (CEDAP)¹⁰. European Association for Professions in Biomedical Sciences¹¹.

Forssman (FORS) system is a new histo-blood group system with only one antigen. This Forssman (FORS1) antigen is expressed in erythrocytes, body fluids, several cells types and organs according to the species involved. Humans are Forssman negative, so the occurrence of antibodies Anti-FORS1 is highly common. However, there are individuals that are Forssman positive. Several studies suggest that the FORS1 antigen might have a key role in carcinogenesis. In this study, the aim was to determine FORS1 antigen expression in gastrointestinal cancer samples and compare the expression in normal and neoplastic tissue.

The expression of FORS1 antigen was analyzed using immunohistochemistry on gastrointestinal tumor and normal samples. The present study compared FORS1 expression in normal and tumor tissues, and the associated FORS1 expression pattern of differentiation with the therapeutic regimen.

The results demonstrated that from the 12 cases studied, 8 cases presented weak expression, 2 cases presented moderate expression of FORS1 antigen and 5 showed strong expression of FORS1 antigen in the cytoplasm of tumor cells. The results demonstrated that the intensity and extension of immunostaining differ according to the differentiation profile, suggesting that areas with a well-differentiated tumor showed higher expression of FORS1 antigen, whereas poorly differentiated areas presented less expression of FORS1 antigen. Samples from patients who performed chemotherapy regimens showed less Forssman expression, compared to patients who underwent surgery, suggesting that FORS1 antigen may have a relevant role in gastrointestinal carcinogenesis.

Key words: Forssman Antigen, gastrointestinal cancer, immunohistochemistry, antibodies.

Introduction

John Frederick Forssman discovered the Forssman (FORS1) antigen (Ag) in 1911, after injecting rabbits with a suspension of kidney tissue from a guinea pig. The antibodies produced by rabbits were found to lyse erythrocytes in the presence of the complement proteins.¹ FORS1 antigen is a heterophile glycosphingolipid antigen, structurally characterized as GalNAc α 1-3GalNAc β 1-3Gal α 1-4Gal β 1-4Glc β 1-Cer.² In 2012, the International Society of Blood Transfusion recognized the Forssman system as a new histo-blood group system with only one antigen.^{3,4} During the eighties, three

unrelated English families were reported with a blood subgroup called Apae which reacted strongly with *Helix pomatia* lectin, weakly with polyclonal anti-A Ab, but not with monoclonal anti-A antibodies.⁵ However, Svensson *et al.* (2012) demonstrated that the erythrocytes from people of subgroup Apae didn't have A antigen but expressed FORS1 glycolipids instead.⁶ Although the glycosyltransferases from group ABO and Forssman were related they have distinct substrate specificity, and FORS1 antigen is synthesized by Fs-synthase (globoside 3- α -N-acetyl-D-galactosaminyltransferase), which is codified by the gene *GBGT1* located on chromosome 9.⁷ Canine

GBGT1 gene cDNA encoding FORS1 was cloned by Haslam and Baenziger and *GBGT1* and *ABO* genes were found to be paralogous genes that were derived from the same ancestral gene through gene duplication and subsequent divergence.⁸

Humans have been classified as FORS1 negative, so the occurrence of expression of antibodies (anti-FORS1) is common. However, there are some cases of individuals that are FORS1 positive. These individuals have a *GBGT1* gene containing the Arg296Gln substitution, which makes the FORS1 glycolipid synthase capable of catalyzing the final step of FORS1 biosynthesis.^{9,10} The FORS1 antigen is widely but unevenly distributed in the animal kingdom. It is present on sheep erythrocytes and a variety of tissues of different animals such as cat, dog, guinea pig, mouse, horse, chicken, pigeon, and turtle, but it is absent in other animals such as rabbit, rat, pig, cow, monkey, and frog. Thus, species have been classified as FORS1 positive and FORS1 negative depending on the expression of the antigen.^{1,11,12}

A previous study suggested that FORS1 antigen might have a key role in carcinogenesis. FORS1 antigen was described as present in gastric, colon and lung cancers and also that the expression in tissues could be related with the antibody titer in the patient's plasma.^{13,14} Gastrointestinal cancers are one of the most prevalent cancers and consequently a major public health problem.¹⁵ Ono *et al.* demonstrated the presence of FORS1 antigen in the cytoplasm of colon goblet cells, especially those in the transitional mucosa adjacent to a carcinoma. It was demonstrated that 69 of the 70 patients contained the FORS1 antigen.¹⁶ Hirayama *et al.* demonstrated that patients with cancer showed levels of antibodies anti FORS1 lower than the age-matched, sex-matched, and blood type-matched control groups. The study demonstrated that patients with gastric cancer presented lower levels of antibodies than patients with non-gastric cancer. The serum levels of antibodies are also influenced by the histological type of cancer, with serum levels lower among those with differentiated adenocarcinoma and higher among those with poorly differentiated

adenocarcinoma. The study also demonstrated that the levels of FORS1 antibodies increased post-surgically and when there was a recurrence of cancer, the levels of antibodies decreased again.¹⁷

The aim of this study was to identify the FORS1 antigen expression in gastrointestinal cancers and compare the expression of Forssman antigen between normal and neoplastic tissues.

Materials and Methods

Sample Characterization

Tissue samples were from the Hospital Distrital da Figueira da Foz E.P.E. (HDFE, E.P.E.), collected by the surgical team between September 2018 and March 2019. As inclusion criteria, the tissue samples were from gastrointestinal tumors, previously diagnosed as adenocarcinoma as primary tumors. Exclusion criteria, samples could not be from another organ tissue nor from another type of cancer nor have another diagnosed pathology.

All subjects who agreed to participate in the study were briefed about the aim of the study and signed an informed consent document. The study followed the principles of the Declaration of Helsinki for scientific research. The Ethics Committee of HDFE, E.P.E. approved the protocol.

Anti-Forssman antibody concentration

The primary antibody produced by cell line clone M1/22.25.8.HL (ATCC® TIB-121™) was concentrated using a solution of ammonium sulfate (0,55g/mL). Then, transferred to a tube containing 1 mL of the Ab supernatant. One mL of ammonium sulfate solution (Panreac Barcelona, Spain) was slowly added to the tube. The tube was then incubated for 2 hours at 4°C. After incubation, the tube was centrifuged for 20 minutes at 3000 g. At the end of the centrifugation, the supernatant was removed, and the pellet was re-suspended in a solution of 200 mL of phosphate-buffered saline.¹⁸

Immunohistochemistry

Formalin-fixed, paraffin-embedded tissue specimens from 12 patients with gastrointestinal adeno-carcinoma were used for immunohistochemistry staining.

Accepted: January 1, 2021

Corresponding author: Fernando Mendes, Rua 5 de Outubro - SM Bispo Apartado 7006, 3046-854 Coimbra, Portugal
Email: fjmendes@estescoimbra.pt

Through paraffin blocks containing both cancerous and adjacent noncancerous tissue, 3 µm sections were obtained in the microtome and placed on immunohistochemistry positively charged slides.^{19,20}

To increase the tissue adhesion to the slides, the sections were heat fixed in a laboratory stove at 60°C for 1 hour. Next, the slides were dewaxed in xylol and rehydrated in a graded series of ethanol. Before starting immunostaining, and to increase accessibility to the antigen, the slides were incubated with Ultra Cell Conditioning Solution (Ventana Medical Systems, Tucson Arizona, USA), a buffer solution was used in the antigenic retrieval of tissues for 40 minutes at 95°C, pH 8. The activity of endogenous peroxidase was blocked by incubation of the tissues with “Peroxidase Inhibitor” (Ventana Medical Systems, Tucson Arizona, USA) for 8 minutes.

After incubation, a blocking nonspecific antigen binding solution was used to reduce background staining, with a hyperproteic solution “Discovery antibody diluent” (Ventana Medical Systems, Tucson Arizona, USA) for 8 minutes. The slides were then incubated for 1 hour with a primary antibody clone M1/22.25.8.HL (ATCC® TIB-121) which reacts with human and mouse tissues.

The detection of the Ab was made using a multimer “Horseradish peroxidase Multimer” (Ventana Medical Systems, Tucson Arizona, USA) which provides signal amplification, for 8 minutes. After that, a solution of DAB Chromogen (Ventana Medical Systems, Tucson Arizona, USA) and DAB H₂O₂ (Ventana Medical Systems, Tucson Arizona, USA) in equal parts, was placed on the slides for 4 minutes. All incubations were followed by a rinse in a phosphate-buffered Saline solution, “Reaction Buffer 10x” (Ventana Medical Systems, Tucson Arizona, USA) and all the steps in this protocol took place at room temperature, except as noted.^{19,20}

Next, the slides were incubated for 4 minutes with a solution containing copper sulfate (5.0 g/L) in an acetate buffer to amplify DAB signal, “DAB Copper” (Ventana Medical Systems, Tucson Arizona, USA). Finally, nuclear counterstaining was performed for 2 minutes using a hematoxylin solution (Ventana Medical Systems, Tucson Arizona, USA) followed by incubation for 1 minute with a solution to bluing the hematoxylin, DAB Bluing (Ventana Medical Systems, Tucson Arizona, USA). The slides were rinsed in water, dehydrated, cleared, and mounted.

Then the intensity of the immunostaining was observed with a microscope. All slides were classified by three independent observers.

Evaluation of immunostaining

The intensity of immunostaining was evaluated using a scale from 0 to 3, where 0 corresponds to a negative expression of FORS1 antigen, 1 corresponds to a weak expression of FORS1 antigen, 2 corresponds to a moderate expression of FORS1 antigen and 3 corresponds to a strong expression of FORS1 antigen.

Statistical analysis

The IBM SPSS® v.24 (National Opinion Research Center, Chicago, USA) was used for statistical analysis. The Chi-Square test was used to correlate the intensity and differentiation profile.

The One-Way ANOVA was used to relate the extension of immunostaining and the differentiation profile. The differences between the groups were considered statistically significant when assuming a random error of p>0.05, with a confidence level of 95%.

Results

This study included 12 patients that ranged in age from 57 to 89 years old, including 5 females and 7 males diagnosed with gastrointestinal cancer, properly staged according to the TNM system, as well as the therapeutic approach (Table 1).²¹ The respective slide

Table 1 – Characterization according to gender, age, TNM and therapeutic approach of the patients.

Cases	Gender	Age	TNM	Treatment
G1	Male	62	T3N1cM1	Surg + Adjv QT
G2	Female	89	T3N2M1	Surgery
G3	Male	82	T4aN1M0 IVL	Surg + Adjv QT
G4	Male	78	T1N0M0	Surgery
G5	Female	81	T3N0M0	Surg + Adjv QT
G6	Male	73	T4N3bM0 IVL	Surg + Adjv QT Neoadjuvant QT
G7	Female	72	T3N0M0	Surg + Adjv QT
G8	Female	83	T3N0M0	Surgery
G9	Male	76	T2N0M0	Surgery
G10	Male	62	T3N0M0	Surg + Adjv QT
G11	Female	78	T3N2M0	Surg + Adjv QT
G12	Male	57	T4N2bM0	Surg + Adjv QT

Key: IVL – Invasion lymphovascular; T – Size of tumor; N – Number of lymph nodes invaded by tumor cells; M – Metastases; Surg – Surgery; Adjuvant; Chemotherapy – QT

of tissue from each patient was observed and classified according to the differentiation phenotype, as described in Table 2. Of the 12 cases, 5 have differentiated adenocarcinoma, 2 have poorly differentiated adenocarcinoma and 3 have some areas

with differentiated adenocarcinoma and poorly differentiated adenocarcinoma (Table 2). Regarding

Table 2 – Characterization according to differentiation tumor phenotype.

Cases	Differentiation phenotype of the tumors
G1	Differentiated Adenocarcinoma
G2	Poorly Differentiated Adenocarcinoma
G3	Poorly Differentiated Adenocarcinoma
G4	Differentiated Adenocarcinoma
G5	Differentiated Adenocarcinoma
G6	Poorly Differentiated Adenocarcinoma
G7	Differentiated Adenocarcinoma
G8	Poorly Differentiated Adenocarcinoma / Differentiated Adenocarcinoma
G9	Differentiated Adenocarcinoma
G10	Differentiated Adenocarcinoma
G11	Poorly Differentiated Adenocarcinoma / Differentiated Adenocarcinoma
G12	Poorly Differentiated Adenocarcinoma / Differentiated Adenocarcinoma

the FORS1 antigen expression, it was observed that five cases showed weak expression, one case moderate expression of FORS1 and three have strong expression of FORS antigen in the cytoplasm of tumor cells. In two cases areas with weak and strong intensity were observed, cases G8 and G12,

respectively. G11 showed a weak and moderate intensity of FORS1 antigen expression (Table 3).

Table 3 – Intensity and extension of FORS1 antigen expression in tumor tissues

Cases	Gender	Age
G1	Weak	40%
G2	Weak	20%
G3	Moderate	90%
G4	Weak	50%
G5	Strong	80%
G6	Weak	90%
G7	Weak	60%
G8	Weak / Strong	30% / 70%
G9	Strong	70%
G10	Strong	80%
G11	Weak / Moderate	40% / 90%
G12	Weak / Moderate	50% / 90%

Figure 1 shows negative and positive controls. The negative control was a tonsil sample (Fig 1a) and the positive controls were colon adenocarcinoma, lung adenocarcinoma and gastric adenocarcinoma, Figures, 1b, 1c and 1d, respectively. The results suggested that the intensity and the extension of the immunostaining were associated with the differentiation profile, $p < 0,038$ and $p < 0,003$, as presented in Figure 2, which

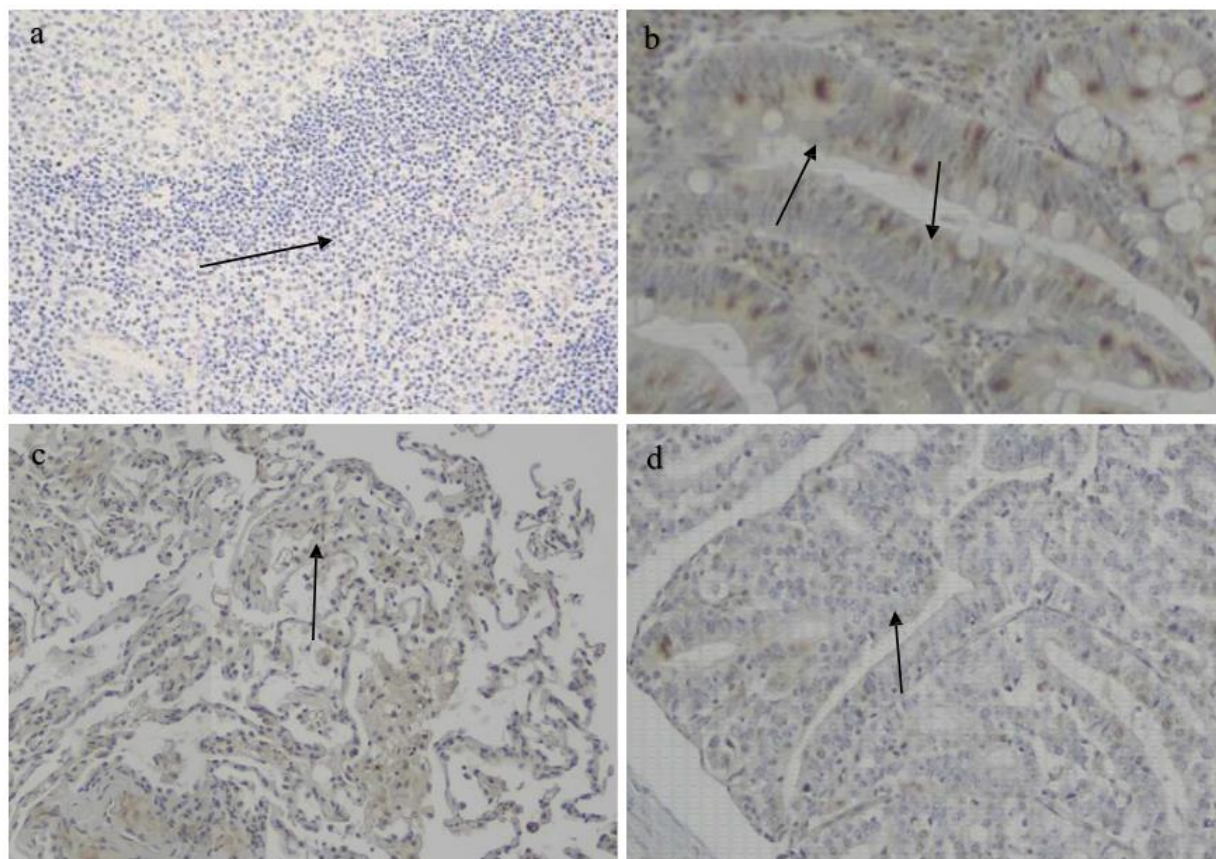


Figure 1: Immunostaining of Negative control and Positive control of FORS1 antigen. The slides were observed under the Olympus U-D30 optical microscope (Olympus, Tokyo, Japan), 100x magnification and photographed with an Olympus SC30 camera (Olympus, Tokyo, Japan); a) negative control of FORS1 antigen using normal tissues (arrow- blue cytoplasm of cells); b) positive control of FORS1 antigen using colon adenocarcinoma (arrow- brown cytoplasm of cells); c) positive control of FORS1 antigen using lung adenocarcinoma (arrow- brown cytoplasm of cells); d) positive control of FORS1 antigen using gastric adenocarcinoma (arrow- brown cytoplasm of cells).

is representative of FORS1 antigen expression. Interestingly the results also suggest that areas with well-differentiated tumor showed higher expression of FORS1 antigen, while areas poorly differentiated showed lower expression of FORS1 antigen.

Surprisingly, three samples of the same tumor well-differentiated areas with higher expression of FORS1 antigen, and poorly differentiated areas showed lower expression of FORS1 antigen.

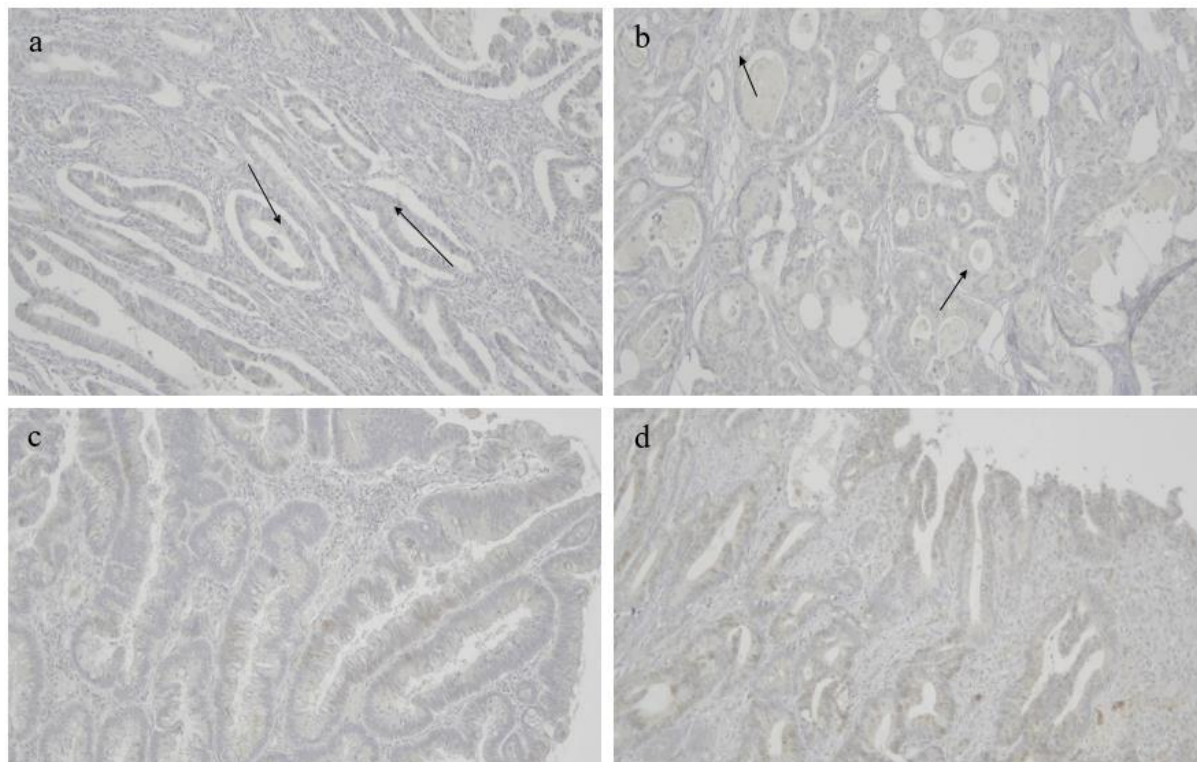


Figure 2: Figure representative of FORS1 antigen expression. The slides were observed under the Olympus U-D30 optical microscope (Olympus, Tokyo, Japan), 100x magnification and photographed with an Olympus SC30 camera (Olympus, Tokyo, Japan); a) The picture shows the presence of a weak expression of FORS1 antigen in the cytoplasm of cells of a poorly differentiated adenocarcinoma in Case G1 (T3); b) The picture shows the presence of a moderate expression of FORS1 antigen in the cytoplasm of cells of a differentiated adenocarcinoma in Case G3 (T4); c) The picture shows the presence of a strong expression of FORS1 antigen in the cytoplasm of cells of a differentiated adenocarcinoma in Case G9 (T2); d) The picture shows the presence of a weak/strong expression of FORS1 antigen in the cytoplasm of cells of a differentiated adenocarcinoma in Case G8 (T3).

Discussion

Most people have naturally occurring anti-FORS1 in their plasma, however the expression of FORS1 antigen in tissues has been a challenge. FORS1 antigen was described for the first time in gastric, colon and lung cancer tissues.¹³ The results obtained in the present study confirmed the presence and the expression of FORS1 antigen in tumor tissues of gastrointestinal cancer.

A previous study had suggested a correlation between the FORS antibody titer in the blood and the expression of the FORS1 antigen in tumor tissue, reporting that the titer of FORS antibodies could be associated with the adenocarcinoma differentiation pattern and with antibody serum levels.¹⁷ Lower levels of antibodies were associated with differentiated adenocarcinoma and higher levels of FORS antibodies were observed in cases with poorly differentiated adenocarcinoma.¹⁷

Based on the results observed in the previous study, this study hypothesized that the variation of antibody concentration in the blood could influence the expression of the FORS1 antigen in tissues of tumors. When the FORS antibody titer in the blood is high, the expression of the FORS1 antigen in the tumor tissue should be weak. When the FORS antibody titer in the blood is low, the expression of the FORS1 antigen should increase. The results of this study support the an inverse relationship between FORS antibody levels and FORS1 antigen expression in gastrointestinal cancers. Furthermore, besides the correlation between FORS1 antigen expression and FORS antibody levels with the differentiation pattern (differentiated adenocarcinoma and poorly differentiated adenocarcinoma), the association with the tumor staging also occurred (T1 to T4). In fact, patients within group T1 and T2 exhibit lower antibody levels, and higher expression of FORS antigen in tumor tissues. Patients in group T3 and T4 presented higher levels of FORS antibody, but lower

expression of FORS1 antigen in tumor tissues. The subset of patients in the study underwent different therapeutic regimens, namely surgery or adjuvant chemotherapy. The intensity and extent of FORS1 antigen expression in tumor tissues was different between the patients who underwent surgery and the group of patients who underwent surgery plus adjuvant chemotherapy. Tumor tissues obtained from patients who underwent chemotherapy showed a weaker FORS1 antigen expression than patients who underwent only surgery. This decrease in the expression of the FORS1 antigen may be associated with the death of the tumor cells that express FORS1 antigen suggesting that there is a relationship between the therapy regimen and the expression of the FORS1 antigen in the tumor tissue. Based on the above, FORS1 antigen expression could be associated with the prognostic and therapeutic approach in cases of gastrointestinal cancer.

The authors are aware of the limitations of the study related to the small number of clinical cases and the inability to measure FORS antibody levels in the blood due to lack of patient's serum.

References

1. Yamamoto M, Cid E, Yamamoto F. Molecular genetic basis of the human Forssman glycolipid antigen negativity. *Sci Rep*. 2012;2:975.
2. Siddiqui B, Hakomori S. A revised structure for the Forssman glycolipid hapten. *J Biol Chem*. 1971 Sep;246(18):5766–9.
3. Svensson L, Hult AK, Stamps R, Angstrom J, Teneberg S, Storry JR, et al. Forssman expression on human erythrocytes: biochemical and genetic evidence of a new histo-blood group system. *Blood*. 2013 Feb;121(8):1459–68.
4. Jesus C, Hesse C, Rocha C, Osório N, Valado A, Caseiro A, et al. Prevalence of antibodies to a new histo-blood system: the FORS system. *Blood Transfus*. 2018 Feb;16(2):178–83.
5. Stamps R, Sokol R, Leach M, Herron R, Smith G. A new variant of blood group A. *Apae. Transfusion*. 1987 Jul;27(4):315–8.
6. Svensson L, Hult AK, Stamps R, Ångström J, Teneberg S, Storry JR, et al. Forssman expression on human erythrocytes: Biochemical and genetic evidence of a new histo-blood group system. *Blood*. 2013 Feb;121(8):1459–68.
7. Taniguchi N, Yokosawa N, Narita M, Mitsuyama T, Makita A. Expression of Forssman

antigen synthesis and degradation in human lung cancer. *J Natl Cancer Inst*. 1981 Sep;67(3):577–83.

8. Haslam DB, Baenziger JU. Expression cloning of Forssman glycolipid synthetase: a novel member of the histo-blood group ABO gene family. *Proc Natl Acad Sci U S A*. 1996;93(20):10697–702.
9. Kijimoto S, Ishibashi T, Makita A. Biosynthesis of Forssman hapten from globoside by alpha-N-acetylgalactosaminyltransferase of guinea pig tissues. *Biochem Biophys Res Commun*. 1974 Jan;56(1):177–84.
10. Yamamoto M, Cid E, Yamamoto F. Crosstalk between ABO and Forssman (FORS) blood group systems: FORS1 antigen synthesis by ABO gene-encoded glycosyltransferases. *Sci Rep [Internet]*. 2017;7(September 2016):41632. Available from: <http://dx.doi.org/10.1038/srep41632> <http://www.nature.com/articles/srep41632> <http://www.ncbi.nlm.nih.gov/pubmed/28134301> <http://www.pubmedcentral.nih.gov/articlerender.fcgi?artid=PMC5278553>
11. Kaczmarek R, Buczkowska A, Mikołajewicz K, Krotkiewski H, Czerwinski M. P1PK, GLOB, and FORS Blood Group Systems and GLOB Collection: Biochemical and Clinical Aspects. Do We Understand It All Yet? *Transfus Med Rev*. 2014;28(3):126–36.
12. LEDUC EH, TANAKA N. A study of the cellular distribution of Forssman antigen in various species. *J Immunol*. 1956 Sep;77(3):198–212.
13. Hakomori S, Wang SM, Young WW. Isoantigenic expression of Forssman glycolipid in human gastric and colonic mucosa: its possible identity with "A-like antigen" in human cancer. *Proc Natl Acad Sci U S A*. 1977 Jul;74(7):3023–7.
14. Young WW, Hakomori SI, Levine P. Characterization of anti-Forssman (anti-Fs) antibodies in human sera: their specificity and possible changes in patients with cancer. *J Immunol*. 1979 Jul;123(1):92–6.
15. Ferlay J, Colombet M, Soerjomataram I, Mathers C, Parkin DM, Piñeros M, et al. Estimating the global cancer incidence and mortality in 2018: GLOBOCAN sources and methods. *Int J Cancer [Internet]*. 2019 Apr 15 [cited 2020 Jul 7];144(8):1941–53. Available from: <https://onlinelibrary.wiley.com/doi/abs/10.1002/ijc.31937>
16. Ono K, Hattori H, Uemura K, Nakayama J, Ota H, Katsuyama T. Expression of Forssman antigen in human large intestine. *J Histochem Cytochem*.

1994;42(5):659–65.

17. Hirayama R, Hirokawa K, Takagi Y, Utsuyama M, Maejima S, Takemura K, et al. Changes in serum levels of Forssman-like antibody in patients with gastric cancer. *Cancer*. 1989;63(8):1528–33.

18. Wingfield PT, editor. Protein Precipitation Using Ammonium Sulfate. In: *Current Protocols in Protein Science*. Hoboken, NJ, USA: John Wiley & Sons, Inc.; 2016. p. A.3F.1-A.3F.9.

19. Werner M, Von Wasielewski R, Komminoth P. Antigen retrieval, signal amplification and intensification in immunohistochemistry. *Histochem Cell Biol*. 1996 Apr;105(4):253–60.

20. Werner M, Chott A, Fabiano A, Battifora H. Effect of formalin tissue fixation and processing on immunohistochemistry. *Am J Surg Pathol*. 2000 Jul;24(7):1016–9.

21. Edge SB, Compton CC. The American Joint Committee on Cancer: the 7th edition of the AJCC cancer staging manual and the future of TNM. *Ann Surg Oncol* [Internet]. 2010 Jun [cited 2014 Dec 9];17(6):1471–4. Available from: <http://www.ncbi.nlm.nih.gov/pubmed/20180029>